

Otterbein University

## Digital Commons @ Otterbein

---

Nursing Student Class Projects (Formerly MSN)

Student Research & Creative Work

---

7-2018

### Disseminated Intravascular Coagulation (DIC)

Nicholas A. Brown

Otterbein University, brown1@otterbein.edu

Follow this and additional works at: [https://digitalcommons.otterbein.edu/stu\\_msn](https://digitalcommons.otterbein.edu/stu_msn)



Part of the [Nursing Commons](#)

---

#### Recommended Citation

Brown, Nicholas A., "Disseminated Intravascular Coagulation (DIC)" (2018). *Nursing Student Class Projects (Formerly MSN)*. 317.

[https://digitalcommons.otterbein.edu/stu\\_msn/317](https://digitalcommons.otterbein.edu/stu_msn/317)

This Project is brought to you for free and open access by the Student Research & Creative Work at Digital Commons @ Otterbein. It has been accepted for inclusion in Nursing Student Class Projects (Formerly MSN) by an authorized administrator of Digital Commons @ Otterbein. For more information, please contact [digitalcommons07@otterbein.edu](mailto:digitalcommons07@otterbein.edu).

# Disseminated Intravascular Coagulation (DIC)

Nicholas Brown, BSN, RN

Otterbein University, Westerville, Ohio

## Topic Statement

Investigation of disseminated intravascular coagulation (DIC) in the critical care setting, and how it contributes to multi-system organ failure.

## Introduction

DIC has been widely recognized as a contributing factor in the outcome of several illnesses (Gando, *et al.*, 2016), and is typically a manifestation of an underlying pathologic or disease process (Boral *et al.* (2016). Boral *et al.* (2016) further relays that "DIC is relatively uncommon in the general hospitalized patient but accounts for 9% to 19% of ICU admissions and has a high mortality rate of 45% to 78%." To better understand this complex process, it is important to discuss normal pathogenesis, and what leads to the DIC cascade in critically ill patients.

### Normal hemostasis:

- A localized process
- Outcome is a platelet plug made through platelet adhesion and aggregation
- Secondary fibrin clot through activation of the coagulation cascade
- Leads to the formation of thrombin

(Boral *et al.*, 2016)

### DIC:

- Acquired syndrome characterized by intravascular activation of coagulation
- No specific localization, results from different causes
- Can cause damage to the microvasculature, and can lead to organ dysfunction

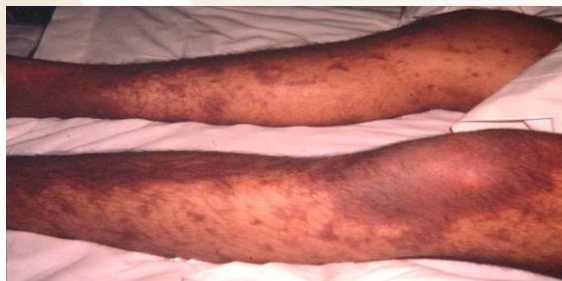(Boral *et al.*, 2016)

## Etiology & Presentation

Clinical conditions identified as etiologies that can lead to the development of DIC (McCance *et al.*, 2014, p. 1044):

- Sepsis/infection (gram-positive or gram-negative bacteria, malaria, fungi, viral hemorrhagic fever)
- Malignancies (metastatic cancer or acute leukemia)
- Pregnancy complications (amniotic fluid embolism, abruptio placentae, intrauterine fetal demise)
- Severe trauma (head injury, burns, etc.)
- Liver disease
- Immunologic reactions (severe anaphylaxis, hemolytic transfusion reactions)
- Vascular abnormalities (giant hemangiomas, large aortic aneurysms)
- Hypoxia

(Levi, 2018)

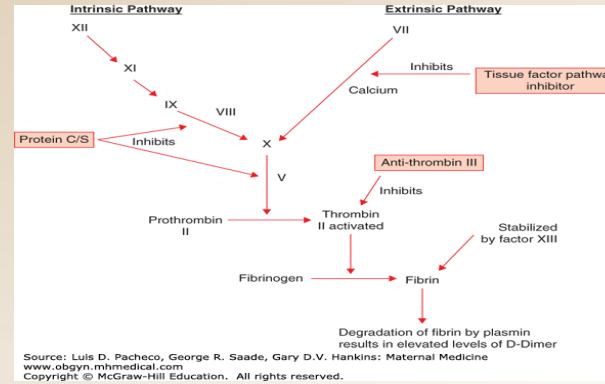


<https://step1.medbullets.com/hematology/114067/disseminated-intravascular-coagulation-dic>

## Signs & Symptoms

Depends on underlying disease process, and whether presentation is acute or chronic

- Result of either hemorrhage or thrombosis
- Most common symptom is bleeding from lines and wounds, purpura, petechia, hematomas, bleeding from eyes, nose, gums
- Can lead to shock; most demonstrate bleeding from 3 or more unrelated sites (McCance *et al.*, 2014, p. 1046)
- Symptoms of thrombosis are not quite as evident-determines the degree of morbidity and risk of death (McCance *et al.*, 2014, p. 1046)
- Asymptomatic to life-threatening symptoms-difficult for nurses to identify in an acute presentation



## Underlying Pathophysiology

The pathophysiology of DIC is complex, and "A variety of mechanisms contributing to the derangement of coagulation in DIC have been elucidated." (Levi, 2018). The significance of this process is inherent in the fact that a variety of factors, such as endothelial injury and inflammation, can initiate DIC (McCance *et al.*, 2014, p. 1045).

- Suppression of normal homeostasis
- Tissue factor (TF) release by endothelium or monocytes
- TF initiates the coagulation cascade, leading to thrombin activation, production of fibrin, and polymerization in a fibrin clot (McCance *et al.*, 2014, p. 1045)
- Clot digestion through plasmin activity → fibrin degradation products
- Tumor necrosis factor- $\alpha$  inhibits plasmin generation → diminished fibrinolysis
- Further induction of cytokine release by monocytes
- Coagulation cascade, including thrombin, activates inflammatory systems, as well as the kinin and complement systems
- Mediators produced affect vascular endothelium → increased permeability
- Contributes to hypotension and potential shock
- Uncontrolled consumption of platelets and clotting factors → potential systemic hemorrhages
- Excess activation of coagulation and platelets → systemic microvascular thrombosis → blockage of vessels with progressive ischemia
- Uncontrolled DIC will ultimately lead to multi end-organ failure (McCance *et al.*, 2014, p. 1045)

(Levi, 2018)

## Significance

Though DIC presents in under 20% of ICU admissions, Toh *et al.* (2016) shares that "the presence of DIC increases the chances of mortality beyond those of the primary disease." This is why early recognition is essential, and leads to better outcomes for the affected patient. Recognition of DIC is not an easy task for health care providers as the process has a "dynamic progression" and manifests in a variety of ways (Toh *et al.*, 2016). As the end result of uncontrolled DIC leads to organ failure, prompt recognition and treatment gives patients a better chance at recovery. The significance of this is that organ failure most frequently involves the lungs and kidneys, followed by the brain, heart, liver, spleen, adrenals, pancreas, and GI tract (Boral *et al.*, 2016). Once the cascade has been initiated, providers struggle to control and reverse the damage it causes to critically ill patients.

## Implications for Nursing Care

Quick and accurate clinical diagnosis is critical, therefore nurses need to be aware of what indicators to look for that indicate organ failure. Nurses should assess for:

- Changes in LOC, confusion
- Seizure activity
- Oliguria
- Hematuria
- Hypoxia
- Hypotension
- Hemoptysis
- Chest pain
- Tachycardia

(McCance *et al.*, 2014, p. 1046)

Diagnosis is confusing and difficult, meaning the bedside nurse plays a critical role in early identification of symptoms. The nurse must also be cognizant of the pertinent lab values that drive treatment of DIC:

- Blood component therapy based on lab findings
  - FFP for INR > 1.5
  - Platelet concentrates for platelets < 50,000
  - Cryoprecipitate for fibrinogen < 100 mg/dl
  - RBC for hematocrit < 21%
- (Boral *et al.*, 2016)

## Conclusion

DIC is dynamic and complex, requiring vigilant monitoring from the bedside nurse. Prompt recognition of the underlying disease process is critical for successful patient outcomes, as there is no one lab test that is used to diagnose DIC (McCance *et al.*, 2014, p. 1047). Presentation can range from acute life-threatening to stable chronic, so the clinical course will vary from patient to patient.

## References

- Boral, DO, B., Williams, MD, D., & Boral, MD, MBA, L. (2016). Disseminated Intravascular Coagulation. *American Journal of Clinical Pathology*, 146 (6), 670-680. doi:10.1093/ajcp/aqw195
- Gando, S., Meziani, F., & Levi, M. (2016). What's New in the Diagnostic Criteria of Disseminated Intravascular Coagulation? *Intensive Care Medicine*, 42 (6), 1062-1064. doi:10.1007/s00134-016-4257-z
- Lee, MD, D. H., Lee, MD, Ph.D., B. K., Jeung, MD, Ph.D., K. W., Jung, MD, Y. H., Lee, MD, S. M., Cho, MD, Y. S., Yun, Ph.D., S.-W., & Min, MD, Ph.D., Y. I. (2017). Disseminated Intravascular Coagulation is Associated with the Neurologic Outcome of Cardiac Arrest Survivors. *The American Journal of Emergency Medicine*, 35 (11), 1617-1623. doi:10.1016/j.ajem.2017.04.077
- Levi, M. (2014). Diagnosis and Treatment of Disseminated Intravascular Coagulation. *International Journal of Laboratory Hematology*, 36 (3), 228-236. doi:10.1111/ijlh.12221
- Levi, M. (2018). Pathogenesis and Diagnosis of Disseminated Intravascular Coagulation. *International Journal of Laboratory Hematology*, 40 (1), 15-20. doi:10.1111/ijlh.12830
- McCance, K.L., Huether, S.E., Brashers, V.L., & Rote, N.S. (eds.). (2014). *Pathophysiology: The Biologic Basis for Disease in Adults and Children* (7th ed.). St. Louis, MO: Elsevier/Mosby.
- Toh, MD, C.-H., Alhamdi, Ph.D., Y., & Abrams, Ph.D., S. (2016). Current Pathological and Laboratory Considerations in the Diagnosis of Disseminated Intravascular Coagulation. *Annals of Laboratory Medicine*, 36 (6), 505-512. doi:10.3343/alm.2016.36.6.505

## Additional Sources

- Clark, Steven L. (2015). Chapter 31: *Disseminated Intravascular Coagulopathy*. Retrieved from <https://obgyn.mhmedical.com/content.aspx?bookid=1580&sectionid=96351365>
- Medbullets (2018). *Disseminated Intravascular Coagulation*. Retrieved from <https://step1.medbullets.com/hematology/114067/disseminated-intravascular-coagulation-dic>

Schub, E., & Balderrama, D. (2018). Disseminated Intravascular Coagulation (DIC). *CINAHL Nursing Guide*.



**OTTERBEIN**  
UNIVERSITY